Case Report

# Pleurodesis in Children with Povidone-Iodine: A New Intrapleural Drug

**Alisha Chaudhury, Priya Ramachandran, Uma Devaraj, Uma Maheswari and George A. D'souza**

Department of Pulmonary Medicine, St. John's Medical College, Bangalore (Karnataka), India

## Abstract

Obliteration of pleural space by the adhesion of both the layers of pleura with chemical agents instilled intra-pleurally is termed as pleurodesis. Povidone-iodine is one of the newer agents used for pleurodesis in adults. We report a case of a successful povidone-iodine pleurodesis in a child who presented with recurrent pneumothorax. **[Indian J Chest Dis Allied Sci 2019;61:143-145]**

**Key words:** Povidone-iodine, Pleurodesis, Children, Chemotherapy.

## Introduction

Pleurodesis is defined as intra-pleural instillation of a chemical agent to cause obliteration of pleural space by the adhesion of both the layers of the pleura. Several agents including antibiotics, chemotherapeutic agents, talc, povidone-iodine and autologous blood patch have been used for pleurodesis. Povidone-iodine (iodopovidone) is one of the newer agents for pleurodesis in adults for various indications, such as malignant effusions, chronic transudative effusions and pneumothorax. However, its use in children and infants has been limited mainly to chylothorax.[1] In this report, a case of a successful povidone-iodine pleurodesis in a child who presented with recurrent pneumothorax is being presented.

## Case Report

A 5-year-old female child diagnosed with sputum smear-positive tuberculosis and on anti-tuberculosis treatment presented with recurrent bilateral pneumothorax for which intercostal drainage (ICD) insertions had been performed multiple times at another centre.

At presentation to the Pediatric Emergency department of our hospital, she was severely malnourished and had bilateral pneumothorax with ICD tubes *in situ*. The child was in Type I respiratory failure for which she was intubated and ventilated to maintain respiratory dynamics. Despite all lung protective ventilation measures; the pneumothoraces persisted. Patient was referred to the Pulmonary Medicine department for further work-up and management where a tracheostomy was also performed.

Computed tomography (CT) of thorax showed multiple thin-walled cysts diffusely involving both the lungs (Figure 1). Bilateral perihilar ground-glass opacification with inter-lobular and intra-lobular septal thickening and prominent air bronchograms with preserved lung volumes were also noted. Based on the CT findings, a provisional diagnosis of primary Langerhans cell histiocytosis (PLCH) was made. Open lung biopsy was deferred due to the critical status of the patient. Based on opinions of two experts with respect to the clinical and radiological features, it was decided to treat the patient as PLCH with weekly vinblastine therapy and steroids.[2]

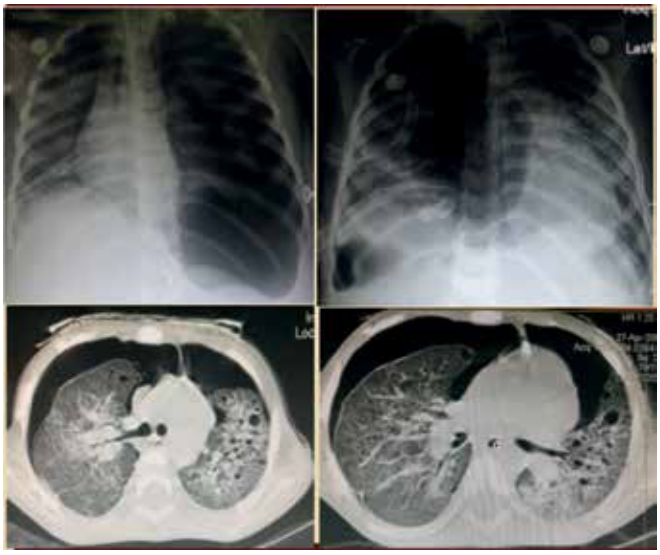

**Figure 1. Chest radiograph (upper panel) and computed tomography (below panel) of thorax showing the presence of bilateral pneumothorax with multiple cysts.**

In view of recurrent bilateral pneumothorax, povidone-iodine pleurodesis was done sequentially on the right (day 15) and left (day 18) sides after cessation of air leak. A mixture of 10% povidone-iodine 10mL mixed with 20mL of 0.9% normal saline with prior lignocaine premedication was instilled intra-pleurally. Repeat chest radiographs showed good expansion of both the lungs (Figure 2). Intercostal drain tubes were removed after two days of pleurodesis and the patient was successfully weaned-off from the ventilator and tracheostomy tube.

She has been on regular follow-up and is receiving treatment for PLCH from the pediatric haemato-oncology department for over a year. There has been marked regression of pulmonary lesions with no recurrence of pneumothorax.

**[Received: November 16, 2017; accepted after revision: February 5, 2018]**

**Correspondence and reprint requests:** Dr Alisha Chaudhury, Department of Pulmonary Medicine, St. John's Medical College and Hospital, John Nagar, Sarjapur Road, Bangalore – 560 034 (Karnataka), India; E-mail: dr.alisha277@gmail.com

**Figure 2. Chest radiograph and computed tomography (post-bilateral povidone-iodine pleurodesis) showing residual cysts but complete resolution of pneumothorax.**

## Discussion

Chemical pleurodesis is one of the accepted interventions in the management of cases of recurrent pleural effusions, and primary or secondary spontaneous pneumothorax.[3,4] Iodopovidone was first used in 1991.[5] However, the precise mode of action of iodopovidone remains unclear.[6] It may be related to the low pH (pH 2.97) of the sclerosing solution, or to the strong oxidative and cytotoxic properties of iodine, which may induce a potent inflammatory response.[7] Mechanism could also be similar to that of talc, *i.e*. production of fibroblast growth factor. It may act as a cytotoxic agent on different tumour cell lines in malignant pleural effusions.[7,8] Historically, talc and tetracycline were used; more recently povidone-iodine is becoming a preferred agent for pleurodesis among respiratory physicians.[9,10]

In adults, use of betadine as a pleurodesing agent has been well documented. The advantages are less chances of relapse, single time intra-pleural instillation, minor side effects and low cost alternative as a sclerosing agent.[11] The need for pleurodesis is also rare in children and is limited to cases of spontaneous primary pneumothorax and chylothorax. The rapid resolution of symptoms of recurrent pneumothorax after pleurodesis in our patient facilitated early removal of chest tubes and faster recovery.

Four cases of povidone-iodine pleurodesis have been described earlier; one patient did not respond to pleuroidesis treatment resulting in an increase of effusion.[1] The patient died of renal failure which was not attributed to the procedure. Pleurodesis was successful in three out of four cases (Table).

Pleurodesis was successfully done for a pre-term infant on ventilator with bilateral pleural effusions (Table). The effusion resolved significantly within 48 hours, but the child died at six weeks due to multi-organ failure.[12] In another study,[13] povidone-iodine pleurodesis was successfully done with the fluid being resolved in 48 hours. The patient had a protracted hospital course as the patient developed respiratory and renal failure. Inspite of the prolonged course, the patient has a successful outcome.[13] In another study[14] with mixed results, two cases of persistent chylothorax had slow resolution of effusion in four to five days. However, the patient with superior venacaval thrombosis did not benefit from the pleurodesis.

A case of congenital bilateral chylothorax presenting as non-immune hydrops in a term male baby at birth with bilateral pleural effusion was managed with ventilation and unsuccessful ICD.[15] Chemical pleurodesis done with 4% povidine iodine on three separate occasions was successful.

In, some cases, the risk of biopsy may outweigh the need for a definitive diagnosis, and therefore, at that time we need to assess the risk/benefit ratio. In case we decide to avoid a biopsy, atleast efforts should be put in to rule out other mimicking conditions, and these patients need

**Table. Comparison of various studies using povidone-iodine for pleurodesis in children.**

| Author | Age | Sex | Indication | PVI Strength (%) | Dose (mL) | Time of Instillation (day) | Instillation B/L/R | Complete or Partial Success | Time to Resolution (days) | Outcome |
|---|---|---|---|---|---|---|---|---|---|---|
| Brissaud *et al*[1] | Newborn | F | Congenital chylothorax | 4 | NA | 65 | B | Yes | 16 | Survived |
| | Newborn | F | Congenital chylothorax | 4 | NA | 11/13 | B | Yes | 7 | Survived |
| | Newborn | F | Congenital chylothorax | 10 | NA | 59 | L | Yes | 6 | Survived |
| | Newborn | F | Congenital chylothorax | 4 | NA | 22/25/26 | B | No | NA | Death |
| Mitanchez *et al*[3] | Newborn | F | Congenital chylothorax | 10 | 5 | 35 | L | Yes | 1 | Survived |
| Murki *et al*[5] | Newborn | M | Congenital chylothorax | 4 | 4 | 30/32 | B | Yes | 30/48 | Survived |
| Hmami *et al*[6] | Newborn | F | Congenital chylothorax | 4 | 5 | 18 | R | Yes | 1 | Survived |
| Resch *et al*[2] | Pre-term | F | Congenital chylothorax | 10 | 5 | 35 | B | Yes | 2 | Death |
| Own case | 5 years | F | Pneumothorax | 10 | 5 | 15/18 | B | Yes | 10 | Survived |

to be monitored by repeated clinical imaging to re-assess the need for biopsy whenever required. Though this was mentioned in context of isolated vertebral body lesion but in our case, the child was critically ill with high ventilator requirements so biopsy was deferred and expert opinions after a multi-disciplinary meeting among the pediatrician hemato-oncologist, radiologist and pulmonologist was taken before initiation of the therapy.

The present case demonstrates a complex clinical scenario involving an infectious process (tuberculosis) superimposed on an underlying cystic lung disease (PLCH) in a malnourished child.[2] Clinical course was complicated by recurrent bilateral pneumothorax with respiratory failure requiring tracheostomy and prolonged mechanical ventilator support, as iodopovidone was commonly used in our institute for pleurodesis in adults, an extensive literature review was also done about the safety of the agent in children before its use. As the long-term effects of talc pleurodesis in children are not known, it was decided to use povidone-iodine, after extensive literature review about the safety of this agent in children.

Based on the evidence from various studies, 20 mL of 10% iodopovidone with 80 mL of 0.9% saline was administered intra-pleurally either through tube thoracostomy or during thoracoscopy in adults.[6] In children, no data on dose is available; but the most common dosage reported in all the case reports was 5mL of 4% povidone-iodine diluted with saline.

Rare side effects in adults like chest pain has been reported in two studies which systematically assessed by the visual analogue scale (VAS).[16,17] Hypotension has also been reported to be vasovagal in origin.[18,19] However, povidone-iodine may cause severe allergic reactions, which could be a medical emergency.[20] In children, frequent use of topical cutaneous povidone-iodine in neonates can induce allergic sensitisation and impairment of thyroid function.[20] It is believed that the risk of hypothyroidism is theoretically greater after the intra-pleural instillation of iodine than after its application to the skin. However, this aspect is still needs to be addressed with more operational research.

In conclusion, this is the first case demonstrating safety and efficacy of povidone-iodine as an agent for pleurodesis in a pediatric case of bilateral pneumothorax with primary Langerhans cell histiocytosis and tuberculosis. Further prospective randomised studies need to be planned to formulate guidelines for the pediatric age group regarding the timing, efficacy and side effects and dosage of sclerosing agents administered in pleurodesis.

## References


1. Brissaud O, Desfrere L, Mohsen R, Fayon M, Demarquez JL. Congenital idiopathic chylothorax in neonates: chemical pleurodesis with povidone-iodine (Betadine). *Arch Dis Child Fetal Neonatal Ed* 2003;88:F531–3.
2. Haupt R, Minkov M, Astigarraga I, Schäfer E, Nanduri V, Jubran R, *et al*. Langerhans cell histiocytosis (LCH): guidelines for diagnosis, clinical work-up, and treatment for patients till the age of 18 years. For the Euro Histio Network *Pediatr Blood Cancer* 2013;60:175–84. Published online 2012 Oct 25. doi: 10.1002/pbc.24367.
3. Musani AI. Treatment options for malignant pleural effusion. *Curr Opin Pulm Med* 2009;15:380–7.
4. Noppen M, De Keukeleire T. Pneumothorax. *Respiration* 2008;76:121–7.
5. Echavarria A, Pinzon V, Bares JP, Fernandez E. Intracavitary treatment of malignant pleural effusion with iodine-povidone. *Rev Med Panama* 1991;16:69–74.
6. Estrada Salo G, Farina Rios C, FiblaAlfara JJ, Gomez Sebastian G, Unzueta MC, Leon Gonzalez C. Spontaneous pneumothorax: pleurodesis with an iodo-povidone hydroalcoholic solution. *Arch Bronconeumol* 2003;39:171–4.
7. Opitz I, Sigrist B, Hillinger S, Lardinois D, Stahel R, Weder W, *et al*. Taurolidine and povidone-iodine induce different types of cell death in malignant pleural mesothelioma. *Lung Cancer* 2007;56:327–36.
8. Agarwal R. Iodopovidone: an inexpensive and effective agent for chemical pleurodesis. *Lung Cancer* 2007;55:253–4.
9. Agarwal R, Khan A, Aggarwal A, Gupta D. Efficacy & safety of iodopovidone pleurodesis: a systematic review & meta-analysis. *Indian J Med Res* 2012:135:297–304.
10. Dey A, Bhuniya S, Datta Chaudhuri A, Pandit S, Saha-Dutta Chowdhury M, Sengupta A, *et al*. Iodopovidone pleurodesis: experience of a tertiary hospital in Kolkata. *Singapore Med J* 2010;51:163–5.
11. Kahrom H, Aghajanzadeh M, Asgari MR, Kahrom M. Efficacy and safety of povidone-iodine pleurodesis in malignant pleural effusions. *Indian J Palliat Care* 2017;23:53–56.
12. Resch B, Freidl T, Reiterer F. Povidone-iodine pleurodesis for congenital chylothorax of the newborn. *Arch Dis Child Fetal Neonatal Ed* 2016;101:F87–8.
13. Mitanchez D, Walter-Nicolet E, Salomon R, Bavoux F, Hubert P. Congenital chylothorax: what is the best strategy? *Arch Dis Child Fetal Neonatal Ed* 2006;91:F153–F156.
14. Scottoni F, Fusaro F, Conforti A, Morini F, Bagolan P. Pleurodesis with povidone–iodine for refractory chylothorax in newborns: personal experience and literature review. *J Pediatr Surg* 2015;50:1722–5.
15. Murki S, Faheemuddin M, Gaddam P. Congenital chylothorax: successful management with chemical pleurodesis. *Indian J Pediatr* 2010;77:332–4.
16. Abdul Aziz DA, Abdul Rahman NA, Tang SF, Abdul Latif H, Zaki FM, Annuar ZM, *et al*. Total pleurectomy as the surgical treatment for recurrent secondary spontaneous pneumothorax in a child with severe pulmonary Langerhans cells histiocytosis. *BMJ Case Rep* 2011;PMID:22674944.
17. Agarwal R, Aggarwal AN, Gupta D. Efficacy and safety of iodopovidone pleurodesis through tube thoracostomy. *Respirology* 2006;11:105–8.
18. Agarwal R, Paul AS, Gupta D, Aggarwal AN, Jindal SK. A RCT on the efficacy of cosmetic talc vs. iodopovidone for chemical pleurodesis. *Respirology* 2011;16:1064–9.
19. Olivares-Torres CA, Laniado-Laborin R, Chavez-Garcia C, Leon-Gastelum C, Reyes-Escamilla A, Light RW. Iodopovidone pleurodesis for recurrent pleural effusions. *Chest* 2002;122:581–3.
20. Wagenfeld L, Zeitz O, Richard G. Visual loss after povidone-iodine pleurodesis. *N Engl J Med* 2007;357:1264–5.